

EVALUATION OF DIAGNOSTIC EFFICACY OF ULTRASONOGRAPHY AND COMPUTED TOMOGRAPHY IN NECK MASSES

Author: Neha Gupta* (1), Neeraj Sainy (1), Rohit Mehrotra (2)

Authors Affiliations: (1) Fellow, (2) Professor & Director, Mehrotra ENT Hospital, Kanpur

ABSTRACT

INTRODUCTION

A neck mass can be frequently seen in clinical practice. The close proximity of various structures in the neck creates a diagnostic problem. The precise anatomical location and imaging appearances are important for accurate diagnosis and formulating the differential diagnoses of neck masses. The present study was undertaken to evaluate diagnostic efficacy of ultrasonography and computed tomography in neck masses.

AIM

To assess the efficacy of Ultrasonography and Computed Tomography in the evaluation of neck masses.

MATERIAL AND METHODS

This study was conducted in the department of E.N.T. in co-ordination with the department of Radiodiagnosis, Oncology and Pathology at LLR & Associated Hospital, GSVM, Medical College, Kanpur. Total number of patients included were 50.

RESULT

Of the 50 patients of age group 3-70 years who presented with neck masses, majority of patients belonged to 20-30 years of age group (10 patients, 20%) with male dominance 62% (31 out of 50 patients). Maximum number of neck swelling were

of lymph node origin 14 (28%). Out of those lymph nodes maximum were malignant. Out of the non nodal masses 36 (72%), maximum were benign.

CONCLUSION

High resolution sonography and color Doppler is a useful modality for diagnostic evaluation of neck masses in every age group. It is simple, non-invasive and inexpensive diagnostic tool. CT ensures accurate anatomical localization and lesion characterization in benign lesions. In malignant tumors, it is useful for staging and provides essential information about the tumor extent that directly affects the surgical approach necessary for curative resection.

Keywords: Ultrasonography, Computed Tomography, Neck Masses

INTRODUCTION

Anatomically, neck is divided into anterior and posterior triangle by sternocleidomastoid muscle. Anterior triangle is bounded anteriorly by – midline of neck, posteriorly by – anterior border of sternocleidomastoid, base by – mandible, and apex lies at manubrium sterni. This triangle is further subdivided by the digastric muscle and superior belly of Omohyoid into – submental, digastric, carotid and muscular triangle.

Posterior triangle is bounded anteriorly by – posterior border of sternocleidomastoid,

posteriorly by – anterior border of trapezius, base by – clavicle, apex lies at superior nuchal line. This triangle is further subdivided by the inferior belly of Omohyoid into – occipital triangle and supraclavicular triangle.

A neck mass can be frequently seen in clinical practice. There is wide range of pathological neck masses from benign inflammatory conditions to frankly malignant lesions, which may be congenital or acquired. These neck mass may be an incidental finding on the general physical examination.

Neck masses can be classified as :

Inflammatory, Congenital/developmental, Neoplastic, Traumatic, Vascular, Neurogenic, Mesenchymal, Thyroid mass, Salivary gland lesion.

A detailed history and physical examination is done. The close proximity of various structures in the neck creates a diagnostic problem. The precise anatomical location and imaging appearances are important for accurate diagnosis and formulating the differential diagnoses of neck masses. Ultrasonography (US) and computed tomography (CT) enable a radiological characterization of normal and diseased structures in the neck in ways that were previously not possible (Sigal R et al,1999)1.

High-resolution ultrasound is an ideal initial imaging investigation for neck tumors (Ahuja AT,2000)2. It is readily available, relatively inexpensive, and does not involve ionizing radiation. Modern ultrasound machines equipped with high-resolution transducers provide excellent spatial and contrast resolution. US is useful in differentiating solid from cystic neck lesions in both adults and children, in recording the size of nodes, and in discriminating high-flow from low-flow vascular malformations. Ultrasound

also has the unique advantage over other imaging techniques in providing reliable, real-time guidance for fine-needle aspiration cytology (FNAC) or core biopsy.

Cross-sectional imaging techniques, such as computed tomography (CT), also play a role in work-up of neck masses. Multi detector CT allows precise preoperative anatomical localization, particularly for more deep-seated and locally extensive lesions; moreover the proximity to vital structures such as nerve bundles and the airway necessitates accurate delineation of these masses. CT gives a greatly improved soft tissue detail and air space definition. With contrast enhanced scans the vascularity of the lesion as well as its relation to vascular structures can be determined. Also the ability of CT to give tissue attenuation values gives a fair insight into the nature of the lesion. It is most useful for large masses where it can show the entire extent of the lesion in the neck and an extension outside the neck (Wholy M et al,1958)3.

Skeletal involvement is also well depicted on CT. It does expose the patients to radiation but the improved visualization of the neck structures far outweighs the radiation risk.

The aim of this study is to evaluate neck masses with Ultrasonography and CT, and also comparing their efficacy.

AIM

To assess the efficacy of Ultrasonography and Computed Tomography in the evaluation of neck masses.

MATERIAL & METHODS

This study entitled - Evaluation Of Diagnostic Efficacy Of Ultrasonography And Computed Tomography In Neck Masses was conducted in the department of E.N.T. in co-ordination with the

department of Radiodiagnosis, Oncology and Pathology at LLR & Associated Hospital, GSVM, Medical College, Kanpur.

Study Design : Prospective study

Study Period : December 2017 to October 2019.

Sample Size : Total number of patients were 50 (including males and females).

INCLUSION CRITERIA

- Patients more than 3 years and less than 70 years of age.
- Patients who presented with a clinically palpable neck mass and underwent investigations(USG, CT scan, FNAC, HPE).

EXCLUSION CRITERIA

- Patients below 3 years of age and above 70 years of age.
- Pregnant and lactating females.
- Post operative patients.
- Patients with contraindications to intravenous administration to contrast medium.
- Patients who did not underwent the required investigations.

METHOD OF COLLECTING DATA

- An informed consent, detailed history, complete general physical, systemic and local examination of swelling was done. Relevant investigations were also done. The data was entered into a specially designed case record form. Data was collected, tabulated and statistically analyzed to draw results.

HIGH RESOLUTION ULTRASONOGRAPHY AND COLOR DOPPLER IMAGING

After informed consent, sonographic examination of the neck was performed in supine position, with the neck of the patient hyperextended.

Examination was done in longitudinal and

transverse planes of the mass in order to evaluate the mass for size, shape, consistency and echogenicity. Its internal architecture, presence of septae, calcification or necrosis was also noted. The scanning was done using slow frame rate, low pulse repetition frequency, a narrow gate, low wall filter setting and high Doppler gain setting in order to maximize Doppler sensitivity.

COMPUTED TOMOGRAPHY

After informed consent, non – enhanced and contrast – enhanced scan using non-ionic contrast media were performed in hyper extended neck position.. Scanning covered the region from the base of the skull to the lung apices using 5-mm collimation. Multi-planar reconstructions were created in both coronal and sagittal planes using 1mm axial sections. All images were reconstructed with bone algorithm to detect bone and cartilage invasion.

RESULT

In our study, 50 patients of age group 3-70 years who presented with neck masses were included. Majority of patients belonged to 20-30 years of age group(10 patients, 20%) and 40-50 years (10 patients, 20%) Minimum patients belonged to age group 50-60 years(4 patients, 8%).

Table 1 : AGE WISE DISTRIBUTION OF PATIENTS

Sr. No.	Age (years)	No. of cases	Percentage(%)
1.	0 – 10	5	10
2.	10 – 20	7	14
3.	20 – 30	10	20
4.	30 – 40	6	12
5.	40 – 50	10	20
6.	50 – 60	4	8
7.	60 – 70	8	16
	TOTAL	50	100

We observed male dominance – 62% (31 out of 50 patients) over female–38% (19 out of 50 patients) in our study.

Table 2 : SEX WISE DISTRIBUTION OF PATIENTS

Sr. No.	Sex	No. of cases	Percentage(%)
1.	Male	31	62
2.	Female	19	38
Total		50	100

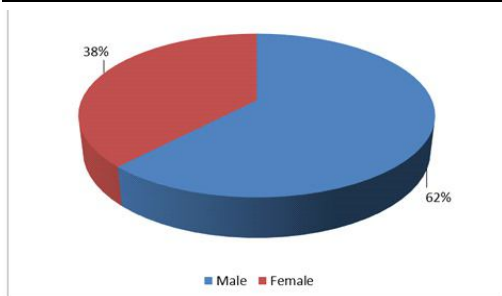


Fig. 1: Sex wise distribution of Patients

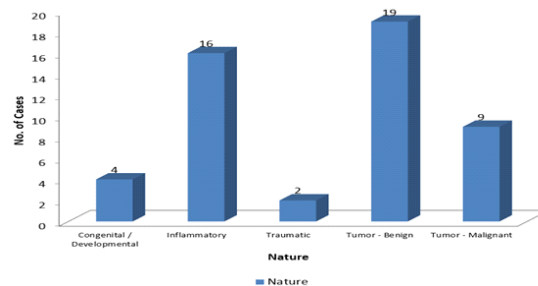
Maximum number of cases were benign tumors-19/50 cases (38%), followed by inflammatory swelling-16/50 cases (32%).

Minimum were of traumatic swelling-2/50 cases (4%).

TABLE 3 : DISTRIBUTION ACCORDING TO NATURE OF MASS

Sr. no.	Nature	No. of cases	Percentage(%)
1.	Congenital /Developmental	4	8
2.	Inflammatory	16	32
3.	Traumatic	2	4
4.	Tumor-Benign	19	38
5.	Tumor-Malignant	9	18
TOTAL		50	100

Fig. 2: Distribution according to nature of mass



In our study we observed that maximum number of neck swelling were of lymph node – 14/50 cases(28%). While minimum were from vascular, lymphatic, thyroglossal duct and 2nd branchial cleft.

TABLE 4 : DISTRIBUTION ACCORDING TO TISSUE OF ORIGIN

S.NO.	TISSUE OF ORIGIN	NO. OF CASES	%
1.	Lymph node	14	28
2.	Thyroid gland	8	16
3.	Submandibular gland	6	12
4.	Parotid gland	3	6
5.	Soft tissue neck	5	10
6.	Subcutaneous plane	2	4
7.	Epidermal	4	8
8.	Fat	2	4
9.	Nerve	2	4
10.	Vascular	1	2
11.	Thyroglossal duct	1	2
12.	2 nd branchial cleft	1	2
13.	Lymphatic system	1	2
TOTAL		50	100

On ultrasonography, 39/50 cases (78%) were true positive and 11/50 cases (22%) were false negative.

TABLE 5 : HISTOPATHOLOGICAL AND RADIOLOGICAL EVALUATION OF ULTRASOUND

		Ultrasound	
		No. of cases	%
Histopathological	True Positive	39	78
	False Negative	11	22
TOTAL		50	100

On Computed Tomography, 48/50 cases(96%) were true positive and 2/50 cases (4%) were false negative.

TABLE 6 : HISTOPATHOLOGICAL AND RADIOLOGICAL EVALUATION OF COMPUTED TOMOGRAPHY

		CT Scan	
		No. of cases	%
Histopathological	True Positive	48	96
	False Negative	2	4
TOTAL		50	100

On comparison between CT scan and USG :

- True positive on both USG and CT were 39/50 cases (78%)
- True positive on USG but False negative on CT were 0 cases (0%)
- True positive on CT but False negative on USG were 9 cases (18%)
- False negative on both USG and CT were 2 cases (4%)

TABLE 7 : COMPARISON BETWEEN CT SCAN AND USG

		Ultrasound		
		Positive	Negative	Total
CT Scan	Positive	39 cases (78%)	9 cases (18%)	48 (96%)
	Negative	0 cases (0%)	2 cases (4%)	2 (4%)
Total		39 (78%)	11 (22%)	50 (100%)

DISCUSSION

This prospective study on EVALUATION OF DIAGNOSTIC EFFICACY OF ULTRASONOGRAPHY AND COMPUTED TOMOGRAPHY IN NECK MASSES included 50 cases of neck masses of age group 3-70 years, done between December 2017 to October 2019. USG and CT Scan were done and the masses were characterized based on location, morphological characteristics and enhancement pattern. The extent was outlined in terms of involvement of adjacent structures, vessels and lymphadenopathy.

In this study, the incidence of benign tumor were 19 out of 50 patients(38%) , inflammatory lesion were 16 / 50 (32%). Only 4 were congenital/developmental and 2 were traumatic neck swelling indicating their low prevalence, this coincide with study of Cunningham (1987)4.

Among the malignant group those presented with secondary in neck, the incidence of 'Growth Larynx' was maximum. Malignant lesion in this study occurred mainly in age group of 40–60 years , which is similar to the study of Mohammad ShadabAlam et al(2017)5.

In the present study overall male patient were much more affected than female.

Thyroid swelling were more in female than male. This coincide with study of Tunbridge et al(1977)6. Among malignant group of swelling presenting as

a neck mass, growth larynx was commonest, followed by growth oral cavity and oropharynx. In almost all cases, the histopathological finding was squamous cell carcinoma. This is similar with finding of RJ Sanderson et al(2002)7, who observed laryngeal carcinoma as most common head and neck carcinoma and histologically more than 90% were squamous cell carcinoma.

Lymph node

In our study 14/50 cases(28%) were of lymph node origin.

Out of those 7 were metastatic lymph nodes – 6 cases due to carcinoma larynx and 1 due to carcinoma oral cavity and oropharynx. All were histopathologically proven to be squamous cell carcinoma of different grades (P O-charoenrat et al,2003)8.

4 were tubercular lymph nodes and 2 were due to peritonsillar abscess.

1 was due to Hodgkin's Lymphoma.

Central nodal necrosis

On USG metastatic node is seen as hypoechoic, round and without echogenic hilus. Intranodal necrosis appears as demarcated echogenic focus and is not continuous with adjacent soft tissues. According to King Ad et al(2004)9, necrosis on CT was defined as a focal area of low attenuation with or without a surrounding rim of enhancement.

Extranodal spread

The presence of extra nodal tumour extension was identified as an irregular nodal margin with infiltration around and obliteration of the adjacent fat planes in our study. King AD et al(2004)10 in their study concluded that sensitivity and specificity of CT as 65% and 93% respectively. There is no significant difference between CT and Ultrasound for either sensitivity or specificity for the detection of Extranodal spread.

Evaluation of primary lesion

In 6 out of the 7 cases larynx was the primary site. 3 cases show transglottic spread with invasion of the thyroid cartilage.

1 case was of carcinoma of buccal mucosa.

The extent of the lesions was defined and any additional findings like bone erosion, prevertebral muscle invasion and involvement of adjacent spaces were noted (Ajay K Goutom et al,2017)11.

Lymphoma

1 case was diagnosed as Hodgkins lymphoma, and showed multiple lymph nodes involving multiple levels on USG and CT and on CT the lymph nodes were homogenously enhancing involvement. Lee YY et al (1987)12 described neck nodal involvement in Hodgkin's and Non Hodgkin's lymphoma, as involvement of multiple deep chain lymph nodes which can be unilateral or bilateral and of varying sizes.

Tubercular lymphadenopathy

4 cases of tubercular lymphadenopathy were noted with unilateral cervical lymphadenopathy and parenchymal lesion on Chest X ray and reactive Mantoux. On USG and CT, the tubercular lymph nodes had the appearance of unilateral conglomerate nodal mass with rim enhancement (on CT) and preservation of fascial planes around them. These findings were in accordance with those described by Vaid S et al(2010)13 .

Non nodal masses

Non nodal masses constituted approximately 72.0% of the lesions and included salivary gland lesions (18.0%), thyroid masses (16.0%), masses of neurogenic (4.0%),vascular (2.0%).

Salivary gland lesions

9 cases (18.0%) of salivary gland pathology were observed in the present study which comprised of tumours (5 cases), infections (4 cases)

4 cases were diagnosed as benign tumor –

pleomorphic adenoma. 3 arising from parotid gland and 1 from submandibular gland. Yousem et al(2000)¹⁴, observed that nearly 80% of benign parotid neoplasms are pleomorphic adenomas. They also mentioned that pleomorphic adenomas occur most commonly in middle-aged women.

3 of the cases were seen involving the superficial lobe of the parotid gland which has been reported to be the most common site of involvement.

1 of the cases was diagnosed to have pleomorphic adenomas involving right submandibular glands.

Koral K et al(2003)¹⁵ in their study have reported that the tumour is almost always solitary, and multiple or bilateral pleomorphic adenomas are rare. Cases appeared as heterogeneously / homogenous enhancing, well defined lobulated/smooth lesions on CT. On ultrasonography pleomorphic adenoma appear as well define, homogenous, regular sometime lobulated shape, with poor vascularity (Dumitriu D et al,2010)¹⁶.

Only 1 malignant salivary gland tumour was diagnosed in our study i.e. mucoepidermoid carcinoma involving the left parotid gland. On ultrasound it appeared as a ill defined, heterogeneous, predominantly hypoechoic lesion with moderate vascularity. It was seen as a heterogeneously enhancing lesion with ill defined margins on CT. There was circumferential encasement of ramus. It was not possible to distinguish between the benign and malignant nature of the tumours on both USG and CT. Kim KH et al(1998)¹⁷ in their study concluded that both CT and USG showed a similar level of accuracy in evaluation of salivary gland tumours, and showed a considerable tendency of misdiagnosis. Also that imaging features of a salivary gland mass can support a clinical diagnosis but cannot alone

make a definitive histological diagnosis.

4 cases were diagnosed to be infectious diseases involving the submandibular gland.

Thyroid masses

In our study there were 8 cases which were considered originating from the thyroid gland. Subsequently 7 cases were diagnosed as multinodular colloid goiter and 1 case was proven to be malignant (papillary carcinoma) on FNAC.

As advocated by Laurie A Lovner et al(2003)¹⁸, the main role of cross-sectional imaging in thyroid neoplasms is not in the characterization of an intrathyroid lesion, as there are no imaging findings that are histologically specific. The role of the radiologist is to assess the findings related to a thyroid mass which will influence treatment decisions, including invasion through thyroid capsule and infiltration of adjacent tissues and structures of neck and to identify presence of cervical lymph node metastasis. Accordingly we assessed the following parameters in thyroid masses- size and location of the lesion, presence of calcification, hemorrhage, necrosis, thyroid capsule invasion, vascular invasion, involvement of trachea and oesophagus, mediastinal extension and adenopathy. All patients underwent total thyroidectomy and histopathological examination of the post operative specimen was done. 1 case of papillary carcinoma was misdiagnosed as multinodular goiter on USG and CT which later confirm on FNAC. Shetty SK(2006)¹⁹ in their study concluded that there is no CT feature that distinguishes benign from malignant lesions when correlated to sonographic appearance or histopathology.

Masses of developmental origin

In our study 4 cases were diagnosed as masses of developmental origin which included lymphangiomas (1 case), branchial cyst (1 case), dermoidcyst(1 case) and thyroglossal cyst(1 case).

Masses of neurogenic origin

Two cases of neurogenic tumor were observed in our study, which was seen as an oval hypoechoic mass with posterior acoustic enhancement on ultrasound. On color flow analysis moderate vascularity was seen in the lesion. The lesion appeared as a well defined heterogeneously enhancing lesion in the poststyloidparapharyngeal space on CT.

Masses of vascular origin

One case was diagnosed to have a hemangioma in the neck. Lesion was heterogeneously enhancing with calcific foci suggestive of phleboliths on CT in the anterior triangle of neck. FNAC was done and aspirate contained blood. Patient was given sclerotherapy.

Inflammatory masses

In our study, 16 cases were inflammatory neck masses.

Masses of mesenchymal origin

2 cases of lipoma in the submandibular space, with well defined margins showing uniform attenuation values of -110 to -50 HU, without any contrast uptake on CT were noted. FNAC was done which showed fat cells. The lipoma was excised. Monem M et al(2006)20 described the posterior subcutaneous neck to be the most common site for lipomas in the head and neck.

CONCLUSION

High resolution sonography and color Doppler is a useful modality for diagnostic evaluation of neck masses in every age group. It is simple, non-invasive and inexpensive diagnostic tool. In many clinical conditions it can be used as first line modality for evaluating cervical soft tissue masses especially in young and paediatric populations.

CT ensures accurate anatomical localization and lesion characterization in benign lesions. In malignant tumors, it is useful for staging and provides essential information about the tumor extent that directly affects the surgical approach necessary for curative resection.

DECLARATION

Ethics approval and consent to participate: The study was approved by Institutional Ethics committee.

Conflict of Interests: The authors declares that there are no conflicts of interest.

Funding: The study was self funded

Acknowledgment: None

BIBLIOGRAPHY

1. Sigal R Imaging of cervical masses. J Radiol Dec 1999; 30 (12):1807-15.
2. Ahuja AT. Lumps and bumps in the head and neck. In: Ahuja AT, Evans RM, editors. Practical head and neck ultrasound. London: Greenwich Medical Media Limited; 2000. p. 87e104.
3. Wholy M, Bruwer A, Baker H. The lateral roentogenogram of the neck Radiology 1958; 71:350-356.
4. Michael J Cunningham, Eugene N Myers, Charles D Bluestone. International journal of pediatric otorhinolaryngology 13(3), 279-292, 1987.
5. Alam MS, Siddiqui SA, Perween R. Epidemiological profile of head and neck cancer patients in Western Uttar Pradesh and analysis of distribution of risk factors in relation to site of tumor. J Cancer Res Ther.2017;13(3):430-435.
6. WMG Tunbridge, DC Evered, R Hall, D Appleton, M Brewis, F Clark, J Grimley Evans. Clinical endocrinology 7(6), 481-493, 1977.
7. RJ Sanderson, J A D Ironside BMJ.

- Squamous cell carcinomas of the head and neck, 325(7368), 822-827;2002.
8. P O-charoenrat, G Pillai, S Patel, C Fisher, D Archer, S Eccles, P Rhys-Evans. Oral oncology 39(4), 386-390, 2003.
 9. King AD, Tse GM, Ahuja AT, Yuen EH, Vlantis AC, To EW et al. Necrosis in Metastatic Neck Nodes: Diagnostic Accuracy of CT, MR Imaging, and US. Radiology. 2004;230: 720–726.
 10. King AD, Tse GMK, Yuen EHY, To EWH, Vlantis AC, Zee B et al. Comparison of CT and MR imaging for the detection of extranodal neoplastic spread in metastatic neck nodes. Eur J Radiol. 2004;52:264–2.
 11. Ajay K Goutam, Avadhesh P S Kushwah, SonjjayPande. Ultrasonography and CT evaluation of neck masses. International Journal of Contemporary Medical Research 2017;4(6):1392-1397.
 12. Lee YY, Van Tassel P, Nauert C, North LB, Jing BS. Lymphomas of the head and neck: CT findings at initial presentation. Am. J. Roentgenol. 1987;149:575-558.
 13. Vaid S, Lee YY, Rawat S, Luthra A, Shah D, Ahuja AT. Tuberculosis in the head and neck – a forgotten differential diagnosis. ClinRadiol. 2010;65:769-770.
 14. Yousem DM, Kraut MA, Chalian AA. Major Salivary Gland Imaging. Radiology. 2000;216:19-29.
 15. Koral K, Sayre J, Bhuta S, Abemayor E, Lufkin R. Recurrent Pleomorphic Adenoma of the Parotid Gland in Pediatric and Adult Patients: Value of Multiple Lesions as a Diagnostic Indicator. AJR Am J Radiol. 2003;180:11711174.
 16. Dumitriu D, Dudea SM, Botar-jid C. Ultrasonographic and sonoelastographic features of pleomorphic adenoma of salivary gland. 2010;12:175-83.
 17. Kim KH, Sung ME, Yun JB, Han MH, Baek CH, Chu KC et al. The significance of CT scan or MRI in the evaluation of salivary gland tumours. AurisNasus Larynx. 1998;25: 397402.
 18. Lovner LA. Thyroid and Parathyroid gland. In: Som PM, Curtin HD, editors. Head and Neck Imaging. 4th edition. St. Louis, MO: Mosby. 2003:2134-2216.
 19. Shetty SK, Maher MM, Hahn PF, Halpern EF, Aquino SL. Significance of Incidental Thyroid Lesions Detected on CT: Correlation among CT, Sonography, and Pathology. Am J Roentgenol. 2006;187:1349-1356.
 20. Mohamed H Abd El-Monem, Alaa H Gaafar, Emad A Magdy. The Journal of Laryngology & Otology 120(1),47-55; 2006.

Copyright: © 2023 Gupta N, etal. This is an open-access article distributed under the terms of the Creative Commons Attribution License, which permits unrestricted use, distribution, and reproduction in any medium by the author.

***Corresponding Author:**

Dr Neha Gupta - MBBS, MS ENT
 Fellow at Mehrotra ENT Hospital, Kanpur
 Email: nehagupta0588@gmail.com

How to cite this article

Gupta N, etal - Evaluation Of Diagnostic Efficacy Of Ultrasonography And Computed Tomography In Neck Masses - UPJOHNS; December 23; 11(2); page:25-33
 DOI: <http://doi.org/10.36611/upjohns/volume11/Issue2/4>
 Orchid Id: <https://orcid.org/0000-0003-0087-4181>



This work is licensed under a Creative Commons Attribution 4.0 International License
 Copyright © 2020 –UPJOHNS